

---

**CASE REPORT****An Unusual Presentation of Bilateral Knee Osteoarthritis – A Case Report***Sunil Nadkarni<sup>1</sup> and Shankar Kashyap<sup>2</sup>**Consultant Orthopedic and Spin Surgeon, Pune<sup>1</sup>*

---

**Abstract:****Introduction:**

Tandem spinal stenosis commonly involves the cervical and lumbar spine. The prevalence of incidentally found cervical stenosis on MRI is 23% to 76%. There is paucity of literature regarding management of asymptomatic cervical stenosis with predominant or isolated lumbar symptoms and also the cause of this phenomenon has not been clearly defined.

**Case report:**

We present a case report of a 62 year Indian male presented to us with predominantly bilateral knee pains which was so debilitating that he was able to walk only few steps with stick support. He was considered for total knee replacement initially. He was operated with a cervical laminectomy and his leg symptoms improved drastically after surgery

**Conclusion:**

Lower limb symptoms may present with pathology localized in cervical spine. There may or may not be signs indicating cervical spine involvement. One must have a wider approach and routinely rule out clinically and radiologically whole spine upto cranio-vertebral junction to avoid delayed diagnosis due to false localization of sensory symptoms

**Key words:**

Bilateral Knee, Osteoarthritis, cervical spine, laminectomy

How to cite this article: Sunil Nadkarni and Shankar Kashyap. An Unusual Presentation of Bilateral Knee Osteoarthritis– A Case Report. Walawalkar International Medical Journal 2017; 4(2):51-61,  
<http://www.wimjournal.com>

**Address for correspondence:**

Dr. Sunil Nadkarni, Consultant Orthopedic and Spin Surgeon, Pune, Maharashtra, India

E-mail: sunilnadkarni@gmail.com, Mobile No.: 9822096340

Received date: 14/12/2017

Revised date: 18/12/2017

Accepted date: 20/12/2017

DOI Link: <http://www.doi-ds.org/doi/10.2017-86593362/>

**Introduction**

Tandem spinal stenosis(TSS) is defined as concomitant stenosis at two or more regions of spine usually involving cervical and lumbar level which has been described since the 1960's. <sup>(1,2)</sup> TSS manifests as a mixed picture involving upper and lower motor neuron symptoms and signs – intermittent neurogenic claudication, gait disturbances, paraesthesias with varied involvement of upper and lower limbs. Cervical spine stenosis is traditionally described as sagittal diameter being less than 10mm.<sup>(3)</sup>

In a case of concomitant lumbar and cervical symptoms, surgery for cervical spine halts the progress of clinical worsening of cervical myelopathy. Dilemma arises when patient presents with predominant or isolated lumbar symptoms without cervical symptoms but with signs of cervical myelopathy. Dilemma also arises when these patients have no cervical signs but radiographic evidence of cervical spine stenosis with or without MRI cord signal changes. Incidental asymptomatic

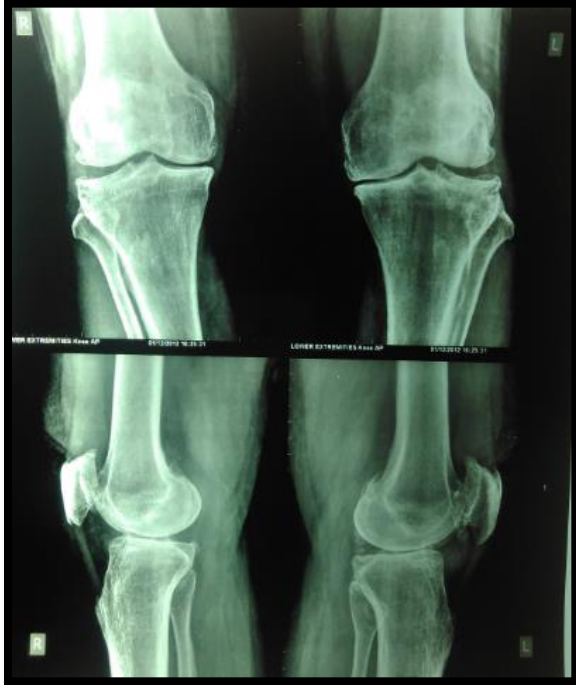cervical spine stenosis in patients with symptomatic lumbar spine spondylosis has been described with incidence being 23% to 76% in previous studies. <sup>(2,4,5)</sup> In these scenarios, indications for surgery of cervical spine have not yet been completely established in literature. <sup>(6)</sup> Recently a case series describes relief of lumbar symptoms of all 6 patients after operating over asymptomatic cervical spine but with positive clinical signs of cervical myelopathy.<sup>(7)</sup>

We present a case report of a 62 year male who presented to us with predominantly leg symptoms with knee bilateral knee pains who was operated with a cervical laminectomy. His leg symptoms drastically improved after surgery

**Case report:**

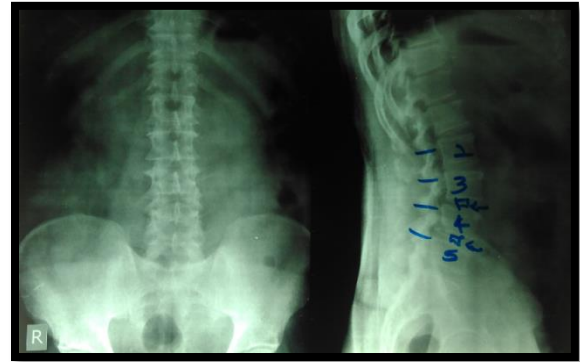A 62 year old male retired gentlemen community ambulatory still actively involved in social service in the local area presented to us with bilateral knee pains and difficulty in walking 5 1/2 years ago. X rays showed mild

to moderate degenerative changes in both knee joints (Fig. 1).



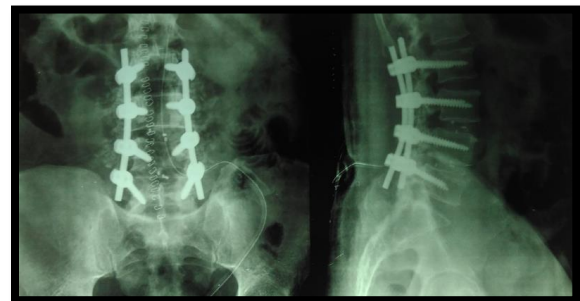
**Fig. 1** bilateral knee standing Xrays showing mild to moderate osteoarthritis

The distribution of pain, claudication symptoms and pain in knees were disproportionate to the degenerative changes seen on Xrays which led us to investigate the lumbar spine. This revealed a degenerative lumbar spondylosis with lumbar stenosis and lysis at L34 L45 levels (Fig 2).



**Fig. 2** Pre-operative standing xrays prior to lumbar spine surgery Dec 2012 showing grade 1 anterolisthesis at L34 and L45 levels

He was operated with L2 to L5 decompression with L34 and L45 transforaminal lumbar interbody fusion and L23 posterolateral fixation fusion (Fig. 3).

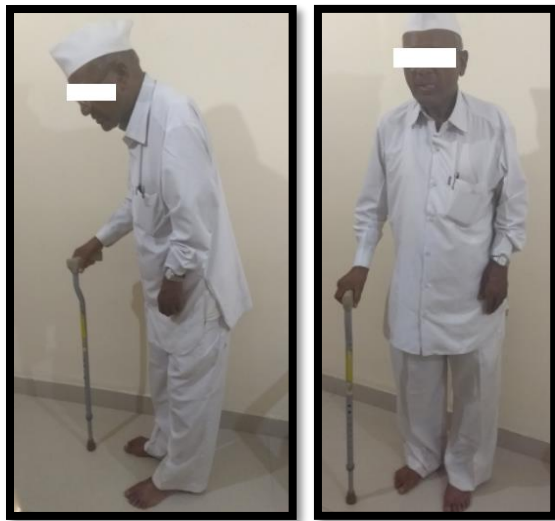

**Fig. 3** Immediate post-operative Xrays showing L2 to L5 decompression with L34 and L45 transforaminal lumbar interbody fusion and L23 posterolateral fixation fusion

He was symptom free in the interim period. There was no neurological deficit before or after his lumbar surgery. The patient

made a good recovery with reduction in pain and improvement in walking distance. He was walking well for almost 5 years.

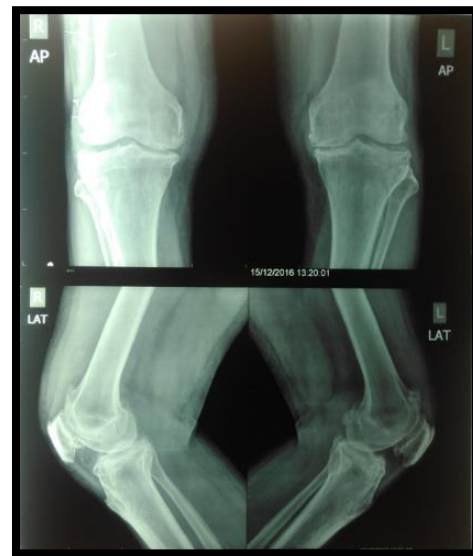After 5 years once again he developed a recurrence of bilateral knee pain of 6 months which failed to respond to conservative treatment. He was barely able to walk few steps with a walking stick support (Fig. 4).



**Fig. 4** Preoperative stooped walking posture

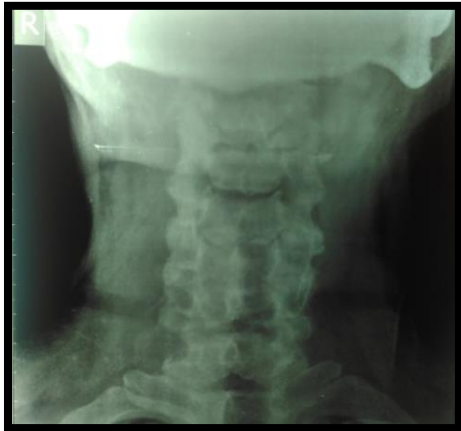He had a pronounced limp and varus in both knees. Bilateral knee joints were mildly tender, with crepitus of knee joint movement. There was no flexion deformity. No ligament laxity in any plane. His VAS score for both leg pains was 10. We decided to evaluate him neurologically for the whole spine because the severity of his symptoms was not corroborating clinically and radiologically. There was no sphincter

involvement and no neurological involvement of upper and lower arms. Deep tendon reflexes were normal and Babinski's sign was normal. X rays revealed medial compartment osteoarthritis (Fig. 5).

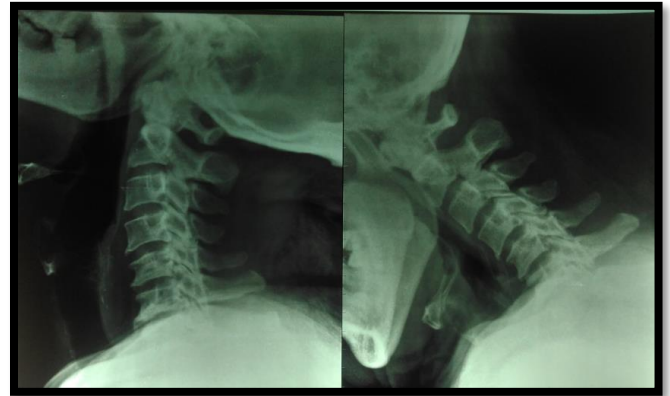


**Fig.5** severe medial compartment osteoarthritis in both knees

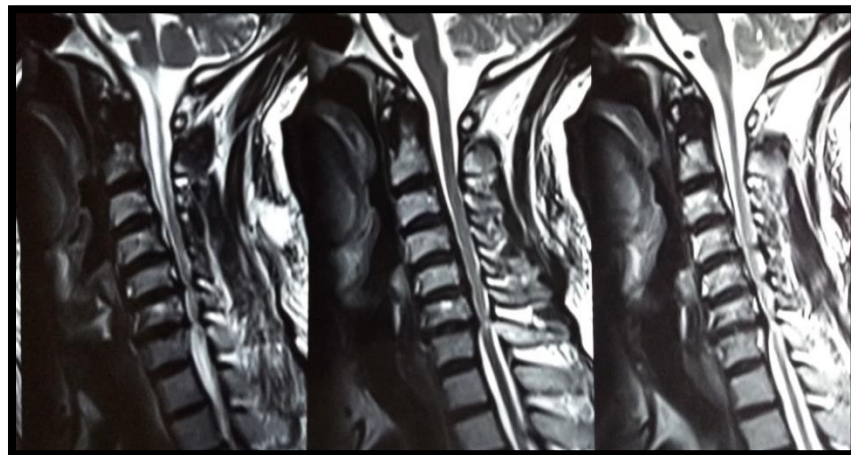
He was being considered initially for bilateral unicompartmental knee replacement. However in view of the distribution and nature of symptoms and lumbar spine being already decompressed it was felt prudent to investigate the spine. This showed a cervical stenosis with hyperintensity cord changes on T2 weighted images (Fig. 6 to Fig. 11).



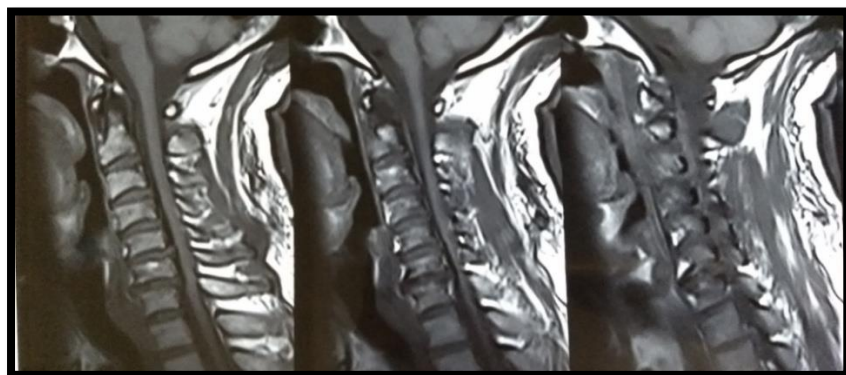**Fig. 6** AP xray image of cervical spine



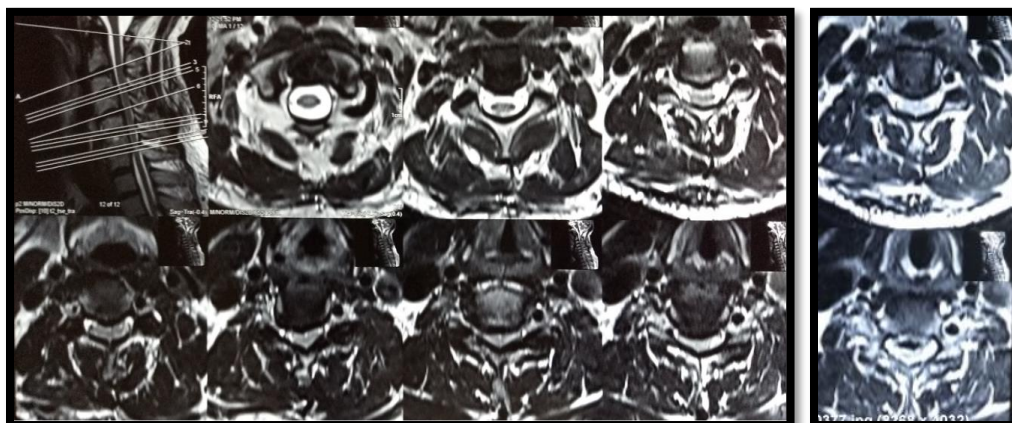
**Fig. 7** Lateral- flexion and extension image of cervical spine showing no instability



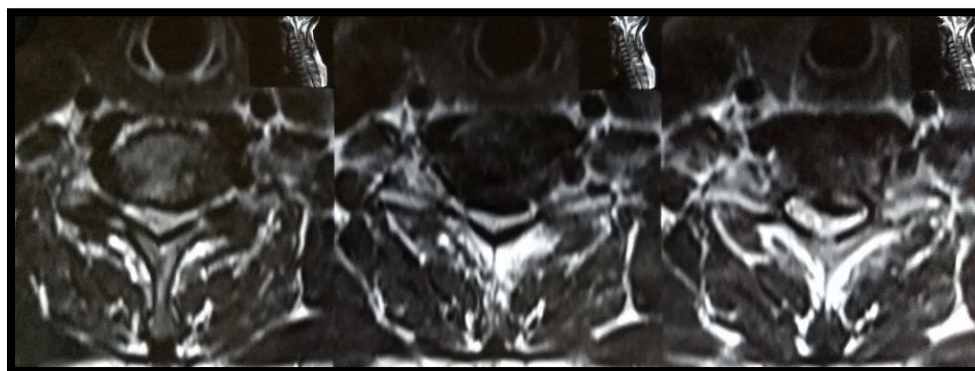**Fig. 8** Sagittal MRI T2 weighted sections showing cervical stenosis from C4 to C7 with cord hyperintensity at C6/7 level



**Fig. 9** Sagittal MRI T1 weighted sections



**Fig. 10** Axial MRI T2 weighted sections till C56 levels showing maximum stenosis at C56 level



**Fig. 11** Axial MRI T2 weighted sections through - C6 lower end plate, C67 disc space, C7 upper end plate from left to right (level with most stenosis of all levels)

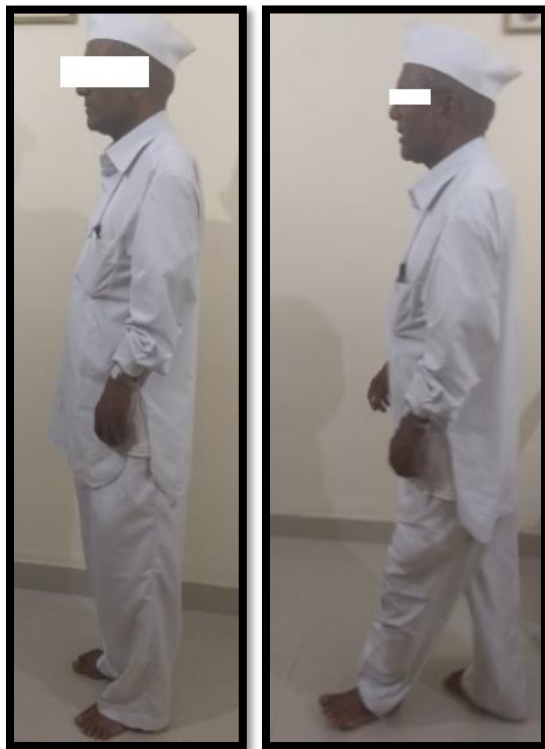His preoperative ODI score was 100 and JOA cervical myelopathy evaluation questionnaire was as given below (Table 1).

Characteristic	Score
Cervical spine function	80
Upper extremity function	78.94
Lower extremity function	27.27
Bladder function	93.75
Quality of Life	77.08

**Table 1-** Preoperative JOA cervical myelopathy evaluation questionnaire

To avoid damage to the cord during intubation a cervical decompression was offered to him before the planned unicompartmental knee replacements for the degenerative knee pain and deformity. A cervical laminectomy was undertaken on. Post operative day he resumed his walking rapidly. On VAS scale his knee pain reduced from 10 before cervical

spine surgery to 1 at from first follow up till final follow up. He walked without assistance. His symptom relief was assessed independently by 2 joint replacement surgeons. They felt it was not necessary to proceed with knee replacements. He was therefore discharged home. At last follow up at 6 months he is walking a distance of 3-4 kms. He does not use any walking aid. His posture has improved considerably. His wife commented that he is now walking straight without a stoop. (Fig. 12)



**Fig.12** walking and standing posture at final followup

He was ambulated next day with walker support initially and was walking without any support at discharge on postoperative day 3. His VAS score at 1 month, 2 month and 4 month followup was 1. His ODI score at 2 month and 4 month followup was 10 and respectively. His JOA cervical myelopathy evaluation questionnaire were as below (Table 2)

Characteristics	2 month followup score	4 month followup score
Cervical spine function	100	
Upper extremity function	100	
Lower extremity function	86.36	
Bladder function	93.75	
Quality of Life	81.25	

**Table 2** - post operative JOA cervical myelopathy evaluation questionnaire

**Discussion:**

Tandem spine stenosis typically involves cervical and lumbar spine with radiological prevalence from 23% to 76% and Molinari et al have mentioned the prevalence of symptomatic patients being from 0.09% to

25%.<sup>(8)</sup> Furthermore, this high occurrence of TSS can be compounded by 5% per year of development of cervical myelopathy from asymptomatic cervical stenosis.<sup>(9)</sup>

False localization signs of spinal cord have been described previously.<sup>(10-18)</sup> False localization leads to delay in diagnosis and a timely diagnosis of cervical myelopathy has been shown to halt the disease progression. Ross et al<sup>(10)</sup> had presented a report with cervical compressive myelopathy with predominantly knee pain. Neo et al<sup>(11)</sup> described ipsilateral popliteal pain caused by cervical disc herniation. Langfitt TW et al<sup>(12)</sup> described pain in the back and legs caused by cervical spinal cord compression. Various explanations have been given,<sup>(14, 17)</sup> like crossing of spinothalamic tracts obliquely 2 or 3 levels above the affected segment, venous stasis causing hypoxic damage of anterior horn cells, lamination of sensory tracts placing the cervical tracts more centrally. None of these theories have been able to give an exact explanation for this phenomenon. Whatever the explanation, irritation of spinothalamic tract tracts or disinhibition of the pain pathways leads to a mis-interpretation of non-nociceptive signals in the ascending tracts even in the absence of any sensory stimuli which leads to false localization.

Some authors have tried to establish clinical symptoms associated with this phenomenon<sup>(11,12,17)</sup> but have failed to give a definitive diagnostic test for it. Sung RD et al have shown that patients with radiculopathy and electrophysiological abnormalities of the cervical cord have a 90% chance of developing symptomatic myelopathy.<sup>(19)</sup> However, usefulness of electrophysiological studies in detecting cervical myelopathy in patients without signs and symptoms has not been described.<sup>(6)</sup> Aebli et al<sup>(20)</sup> in a recent imaging study of trauma patients have shown that a Torg-pavlov ratio of  $<0.7$  was a possible predictor of symptomatic spinal cord injury following minor trauma.

In our case the patient had come with a stooping posture and a waddling gait with symptoms and signs indicating osteoarthritis of both knees. His symptoms were relieved with cervical spine decompression. Along with these evidences and our previous experience of relief of lumbar symptoms in a patient with cervical and lumbar stenosis with symptoms we had an approach towards the thinking to evaluate the whole spine pathology. We routinely screen whole spine with MRI to rule out any proximal pathology. We had not done an NCV study because given the fact that his lumbar spine was already decompressed 4yrs ago with associated



occasional upper limb symptoms it was easier for us to clinically pinpoint the pathology at cervical level. It was further proven with the MRI picture of cervical stenosis and myelopathy.

Daniel Felbaum et al <sup>(7)</sup> in their study had 6 patients who presented with solely leg symptoms. Some patients radiographic findings did not match clinically and some had myelopathic signs without symptoms. All 6 patients had significant postoperative pain relief with mean pre-operative VAS of 6.7 vs. 3.7 postoperative. Our patient did not have any myelopathic signs or symptoms only paraesthesias and pain along C8 distribution albeit C78 region showing no compression on MRI. So clinical picture was corroborating with cervical stenosis seen on MRI which was further justified by visualization of cord hyperintensity seen on T2 weighted MRI images at C67 level. Postoperatively his leg and arm symptoms improved drastically so much that he doesn't feel the need for knee replacement surgery. His walking distance improved. He was walking with a straight posture without support.

This case doesn't necessarily establish a cause and effect relationship however it gives an impetus to have a wider approach when we see a patient with leg symptoms. We need to be careful in ruling out involvement of

upper levels of spine clinically and radiologically before concluding the present symptoms to from lumbar spine because it the cervical cord which connects the brain to the rest of the body neurologically. So it is worth having a thought that pain symptoms in rest of the body can be related to cervical spine or higher. It is also worth contemplating whether having a abnormal flexed posture of the neck in today's world of continuous use of hand held devices and social networking can lead to increase in cervical degenerative process and myelopathy. It is just a conjecture and further studies are needed to establish it.

#### **Conclusion:**

We must have a broader perspective to accommodate the idea of screening the upper levels of spine clinically and radiologically with any patient with predominant or isolated lumbar symptoms. There may or may not be clinical signs of cervical spine involvement. This case report does not establish a definite cause and effect relationship but it gives an impetus to reconsider the classical teaching of evaluating upper levels of spine up to the cranio-vertebral junction.

**Conflict of interest: None to declare**

**Source of funding: Nil**

**References:**

1. Teng P, Papatheodorou C: Combined cervical and lumbar spondylosis. Arch Neurol. 1964, 10:298-308.
2. Hitselberger WE, Witten RM. Abnormal myelograms in asymptomatic patients. J Neurosurg 1968;28:204-6.
3. Torg JS, Pavlov H, Genuario SE et-al. Neurapraxia of the cervical spinal cord with transient quadriplegia. J Bone Joint Surg Am. 1987;68 (9): 1354-70.
4. Lee SH, Kim KT, Suk KS, Lee JH, Shin JH, So DH, et al. Asymptomatic cervical cord compression in lumbar spinal stenosis patients: a whole spine magnetic resonance imaging study. Spine (Phila Pa 1976) 2010;35:2057-63.
5. Kim BS, Kim J, Koh HS, Han SY, Lee DY, Kim KH. Asymptomatic cervical or thoracic lesions in elderly patients who have undergone decompressive lumbar surgery for stenosis. Asian Spine J 2010;4:65-70.
6. Ghobrial GM, Oppenlander ME, Maulucci CM, Viereck M, Prasad S, Sharan AD, Harrop JS: Management of asymptomatic cervical spinal stenosis in the setting of symptomatic tandem lumbar stenosis: a review. Clin Neurol Neurosurg. 2014, 124:114-118.
7. Felbaum DR, Fayed I, Stewart JJ, Sandhu FA. Relief of Lumbar Symptoms After Cervical Decompression in Patients with Tandem Spinal Stenosis Presenting with Primarily Lumbar Pain. Cureus. 2016 Dec 24;8(12):e940. doi: 10.7759/cureus.940.
8. Molinari RW, Gruhn WL, Molinari C (2014) Tandem Spinal Stenosis (TSS): Literature Review and Report of Patients Treated with Simultaneous Decompression. J Spine 4: 200. doi:10.4172/2165-7939.1000200
9. Lee SH, Kim KT, Suk KS, Lee JH, Shin JH, So DH, et al. Asymptomatic cervical cord compression in lumbar spinal stenosis patients: a whole spine magnetic resonance imaging study. Spine (Phila Pa 1976) 2010;35:2057-63.
10. Michael D. Ross, PT, DHSc1; Ryan Elliott, PT. Cervical Cord Compressive Myelopathy in a Man With a Primary Complaint of Knee Pain J Spinal Cord Med. October 2010;33(4):431-434

11. Neo M, Ido K, Sakamoto T, Matsushita M, Nakamura T. Cervical disc herniation causing localized ipsilateral popliteal pain. *J Orthop Sci.* 2002;7(1):147–150.
12. Langfitt TW, Elliott FA. Pain in the back and legs caused by cervical spinal cord compression. *JAMA.* 1967;200(5):382–385.
13. Scott M. Lower extremity pain simulating sciatica: tumors of the high thoracic and cervical cord as causes. *JAMA.* 1956;160(7):528–534.
14. D R S Jameison, E Teasdale, H J Willison. False localizing signs in spinal cord. *BMJ* 1996; 312: 243-4
15. Simmons Z, Biller J, Beck DW, Keyes W. Painless compressive cervical myelopathy with false localizing sensory findings. *Spine* 1986;11:869-72.
16. Yasuoka S, Okazali H, Daube JR, MacCarty CS. Foramen magnum eumors: analysis of 57 cases of benign extramedullary tumors. *J Neurosurg* 1978;49: 828-38.
17. Taylor AR, Byrnes DP. Foramen magnum and high cervical cord compression. *Brain* 1974;97:473-80.
18. Kobayashi S. “Tract pain syndrome” associated with chronic cervical disc herniation. *Hawaii Med J.* 1974; 33(10):376–381.
19. Sung RD, Wang JC. Correlation between a positive Hoffmann’s reflex and cervical pathology in asymptomatic individuals. *Spine (Phila Pa 1976)* 2001;26:67–70.
20. Aebli N, Wicki AG, Ruegg TB, Petrou N, Eisenlohr H, Krebs J. The Torg-Pavlov ratio for the prediction of acute spinal cord injury after a minor trauma to the cervical spine. *Spine J* 2013;13:605