

---

**CASE REPORT****Peripheral Ossifying Fibroma: A Case Series***Neha Thakur<sup>1</sup> and Purushottam Rakhewar<sup>2</sup>**Assistant professor, Department of Dentistry, B.K.L. Walawalkar Rural Medical College & Hospital, Sawarde, Chiplun, Ratnagiri<sup>1</sup>, Professor and HOD of Periodontology, SMBT Dental College, Sangamner, Maharashtra, India<sup>2</sup>.*

---

**Abstract:**

Solitary gingival growths are fairly common oral finding. Intraoral ossifying fibromas have been described in the literature since the late 1940s. Due to clinical and histopathological similarities, some peripheral ossifying fibroma (POFs) are believed to develop initially as a pyogenic granuloma that undergoes fibrous maturation and subsequent calcification. It has been suggested that POF represents a separate clinical entity rather than a transitional form of pyogenic granuloma or irritation fibroma. This paper describes a case series of female patients who reported with gingival growth which was histopathologically confirmed as POF.

**Keywords:**

Gingiva, Fibroma, Ossifying

How to cite this article: Neha Pramod Thakur and Purushottam S.Rakhewar . Peripheral Ossifying Fibroma: A Case Series. Walawalkar International Medical Journal 2017; 4(1):61-65. <http://www.wimjournal.com>

**Address for correspondence:**

Dr. Neha Pramod Thakur, Assistant professor, Department of Dentistry, B.K.L. Walawalkar Rural Medical College & Hospital, Sawarde, Tal- Chiplun, Dist Ratnagiri , Maharashtra State, India.

Email: nehathakurrr@gmail.com, Mobile No. 9673327986

DOI Link: <http://doi-ds.org/doi/10.2017-45311444/>

**Introduction:**

Benign fibrous overgrowths arising from the mucous membrane are termed as fibromas and are more frequent growth in the oral cavity.<sup>(1)</sup> Peripheral ossifying fibroma

(POF) is a reactive soft tissue growth that is usually seen on the interdental papilla.<sup>(2)</sup> It is a non-neoplastic entity, which occurs in response to trauma or irritation.<sup>(3)</sup>

It occurs in the younger age group with a female preponderance. It has a predilection for maxillary arch and most of them occur in the incisor-cuspid region. It can be pedunculated or sessile, usually smooth surfaced and varies from pale pink to cherry red in color. It is believed to comprise about 9% of all gingival growths.<sup>(4)</sup> An important clinical aspect of POF is the high recurrence rate, which ranges from 8% to 45%.<sup>(5)</sup>

This paper describes a case series of female patients who reported with growth on gingiva, which were surgically removed. Further histological examination confirmed the diagnosis of POF.

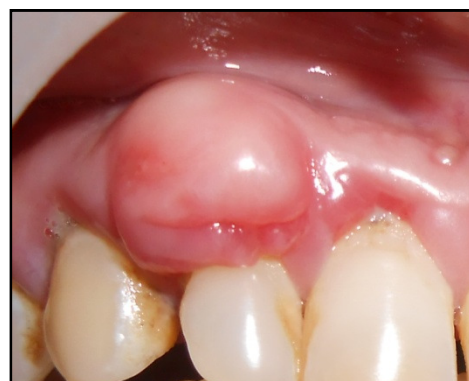#### **Case series:**

##### **Case 1:**

A 48-year-old female patient reported to the department of periodontology with the chief complaint of painless growth on the gingiva in the upper right front region of mouth three years ago. It was gradually increasing in size. The patient did not give any history of trauma.

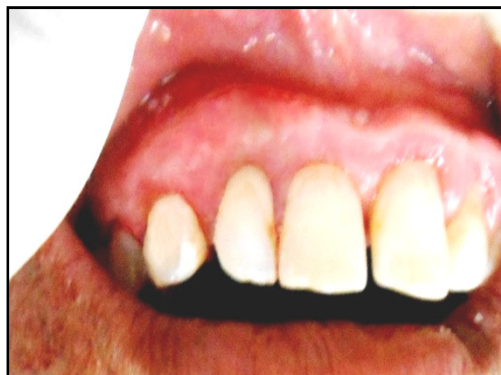Intraoral examination revealed a solitary, sessile gingival growth in maxillary right lateral incisor-canine area. The growth was pale pink in colour, with a size ranging from 1.5 × 1.5 cm. Generalized gingival

inflammation and calculus deposits were seen in patients mouth. **(Fig 1)**



**(Fig 1): At Baseline**

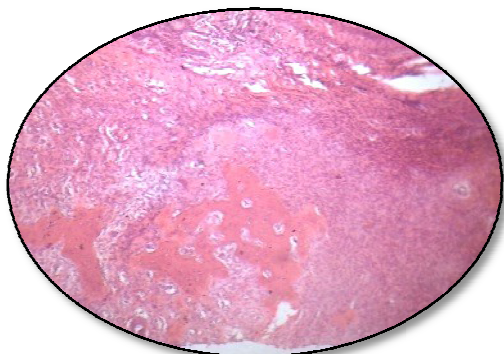
After routine blood examinations treatment was carried out. Phase I therapy was done in the form of scaling and root planning. The lesion was excised completely along with Periosteum under local anesthesia. Scaling and root planning was carried out to remove local irritants. Periodontal pack was given. The pack was removed after 7 days. Healing in area of excision occurred uneventfully within 1 month and the patient was followed up for 6 months after surgical excision. No recurrence was reported. **(Fig 2)**



(Fig 2): 6 months follow up

**Histopathological Examination:**

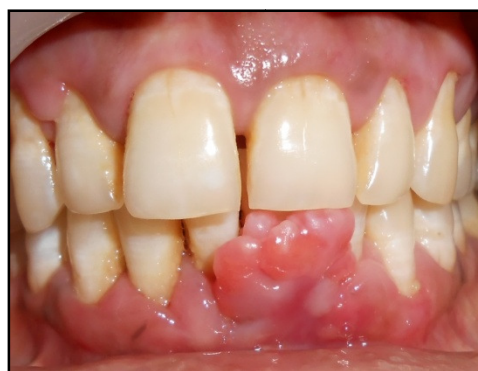Excised tissue growth was given for histological examination. It revealed fibrous lesion covered with stratified squamous epithelium. The underlying connective tissue stroma was highly collagenous with increased fibroblasts. Deeper zone showed numerous blood vessels with endothelial cell proliferation. Bony trabeculae with osteoclasts and lined by osteoblast were seen. (Fig 3)



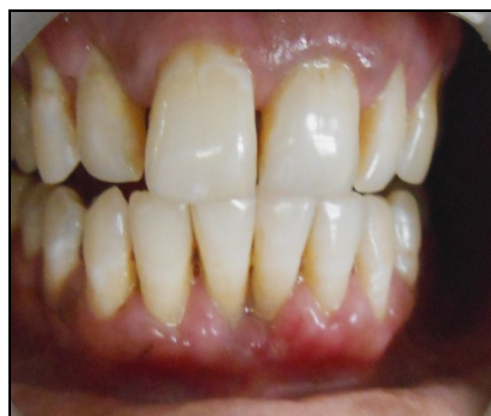(Fig 3): Histopathological examination

**Case 2:**

42 years of female reported to the department of periodontology with overgrowth in the lower front teeth region since 7 months. Intraoral examination revealed irregular, pinkish red gingival growth in mandibular central incisor area measuring 1x1.5 cm. (Fig 4, 5)



(Fig 4): At Baseline

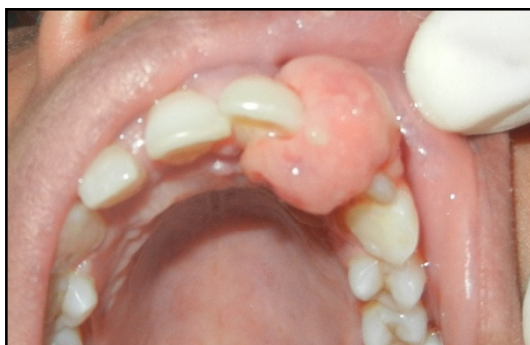

(Fig 5) 6 months follow up

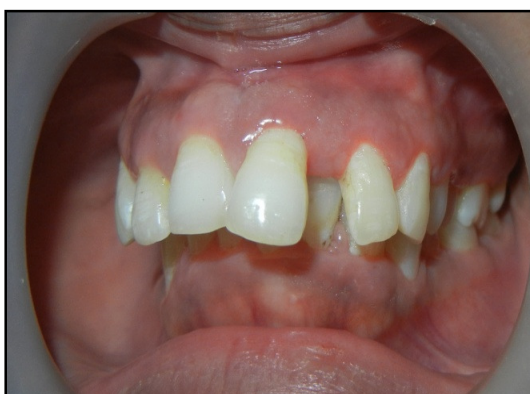**Case 3:**

43 year old female patient showed gingival overgrowth that was exophytic and

arising from interdental papilla between maxillary left central incisor and lateral incisor. It was approximately 2×2.5 cm in size. Lesion was pinkish red, smooth surfaced and firm in consistency. (Fig 6, 7)



(Fig 6) At Baseline



(Fig 7) 6 months follow up

Similar treatments were carried out in case 2 and case 3 as performed in case 1. Both cases were evaluated upto 6 months. No recurrence was found. Histopathology of exisional biopsy of both cases showed increase in fibrous area along with bony trabeculae.

### Discussion:

Peripheral ossifying fibroma has been described as separate lesion since 1872 by Menzel. It is benign, reactive lesion exclusive to gingiva. Dental calculus, plaque, microorganisms, dental appliances, and restorations are considered to be the irritants triggering the lesion. Various nomenclatures had been used for peripheral ossifying fibroma such as peripheral cementifying fibroma, ossifying fibro-epithelial polyp, peripheral fibroma with osteogenesis, peripheral fibroma with calcification, calcifying or ossifying fibrous epulis and calcifying fibroblastic granuloma.<sup>(6)</sup>

POFs usually measure <1.5 cm in diameter even though lesions of 6 cm and 9 cm in diameter are recorded in the literature. The female to male ratio reported in the literature varies from 1.7:1. Most lesions are reported in or after second decade with decrease in its incidence at later age. POF has predilection for maxilla and mostly affects anterior region. But, its occurrence in mandible is not uncommon.<sup>(6)</sup>

The etiology and pathogenesis of POF are not yet clear. Some authors have hypothesized a reactive lesion originating from the periodontal ligament as a result of

irritating agents such as dental calculus, plaque, orthodontic appliances, and ill-fitting restorations. The presence of oxytalan fibers interspersed among the calcified structures, the almost exclusive occurrence on the gingiva, and the age distribution inversely correlating with the number of lost permanent teeth support the hypothesis of an origin from the periodontal ligament. Moreover, the fibrocellular response of POF is similar to that observed in other reactive gingival lesions originating from the periodontal ligament (e.g. fibrous epulis). In vast majority of cases, there is no apparent underlying bone involvement visible on radiograph. However, superficial erosion of bone is noted occasionally.<sup>(7)</sup>

Hormonal influence has also been considered a cause of POF. Its occurrence is rare in prepubertal age. The present case series supports the hormonal influence as a cause of POF along with plaque and calculus. However, a recent study failed to demonstrate the expression of estrogen or progesterone receptors in the proliferating cellular component.<sup>(1)</sup>

*Regezi et al.* found a large number of XIIIa<sup>+</sup> cells, a subset of monocyte/macrophages, in POF and in other oral fibrovascular reactive lesions; it was

hypothesized that these dendrocytes could play a distinct pathogenic role.<sup>(8)</sup> No further studies supporting this hypothesis were found till date.

*Cundiff* observed 16% recurrence rate and a series studied by *Eversole and Robin* showed 20% recurrence rate.<sup>(9)</sup> In the literature, time interval for recurrence is not evident. In the present report the cases were followed up to 6 months. However, no recurrence was seen.

Though the treatment includes local surgical excision and oral prophylaxis, it is necessary to remove all putative risk factors, including plaque, calculus and plaque-retentive restorations to minimize the possibility of recurrence.<sup>(6)</sup>

#### **Conclusion:**

Clinically it is difficult to differentiate between most of the reactive gingival lesions particularly in the initial stages. POF shares a varied clinic-pathological presentation. Surgical excision is considered curative treatment but may present a high recurrence rate compared with other reactive lesions. Therefore it is important to eliminate the etiological factors and the tissue has to be histologically examined for confirmation. It

helps to accurate patient evaluation and management.

**Conflict of interest: None to declare**

**Source of funding: Nil**

**References:**

1. Savitha B, Ruhee L Chawla, Sanjay J Gawali, Alka S Waghmare, Amita D Ahire: Peripheral Ossifying Fibroma: A Case Report. Int J Health Sci Res. June 2013; 3(6):106-109
2. K. S. Poonacha, Anand L. Shigli, Dayanand Shirol: Peripheral ossifying fibroma: A clinical report. Contemp clinic dent. Jan-Mar 2010; 1(1):54-56.
3. Khizer Mohiuddin, N. S. Priya, Shivamurthy Ravindra and Sarvani Murthy: Peripheral ossifying fibroma. J Indian Soc Periodontol. 2013 Jul-Aug; 17(4): 507-509.
4. Bhaskar NS, Jacoway JR: Peripheral Fibroma and Peripheral Fibroma with Calcification: Report of 376 Cases. J Am Dent Assoc. 1966; 73:1312-20.
5. Cuisia ZE, Brannon RB: Peripheral ossifying fibroma – A clinical evaluation of 134 pediatric cases. Pediatr Dent. 2001; 23:245-8.
6. Giovanni Mergoni, Marco Meleti, Simone Magnolo, Ilaria Giovannacci, Luigi Corcione and Paolo Vescovi: Peripheral ossifying fibroma: A clinicopathologic study of 27 cases and review of the literature with emphasis on histomorphologic features. J Indian Soc Periodontol 2015 Jan-Feb; 19(1): 83-87.
7. Meenakshi Bhasin, Vinny Bhasin, and Abhilasha Bhasin.: Case Report Peripheral Ossifying Fibroma. Case Reports in Dentistry. 2013 ;Article ID 497234,1-3.
8. Regezi JA, Nickoloff BJ, Headington JT: Oral submucosal dendrocytes: Factor XIIIa+and CD34+dendritic cell populations in normal tissue and fibrovascular lesions. J Cutan Pathol. 1992; 19:398-406.
9. Jain A, Deepa D: Recurrence of peripheral ossifying fibroma: A case report. People's J Sci Res. 2010; 3:23-5.