
Case Report**Acute myocardial infarction after bee sting: a rare phenomenon**

Rahul Surve¹, Suvarna Patil², Joydeep Ghosh³

Department Of Medicine, BKL Walawalkar Hospital & Medical College,
Ratnagiri, Maharashtra^{1,2}. Specialist Registrar, Department of Oncology,
Tata Memorial Hospital, Parel, Mumbai³.

Abstract

Bee sting is a very common phenomenon in rural population in Maharashtra. It causes an array of symptoms ranging from mild stinging to fatal anaphylaxis. Rapid identification of the physiological abnormality is important life saving measure. Myocardial infarction following bee sting is a very rare phenomenon. There are only case reports till date. The mechanism lies in the activation of the inflammatory cascade due to the bee sting. Here we present a case of bee sting who had myocardial infarction with hemodynamic instability, and has been treated adequately and partially recovered from the same.

Case:

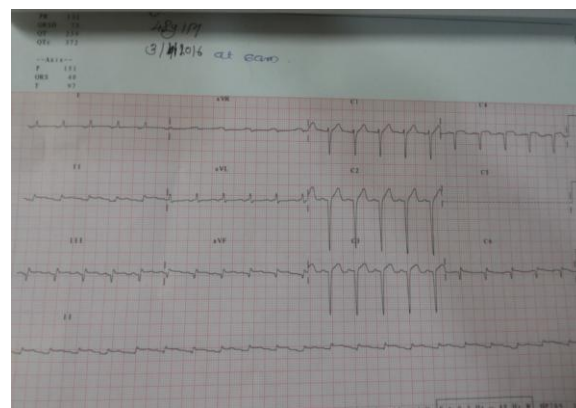
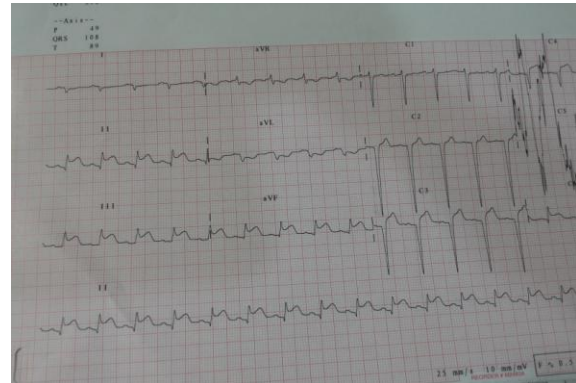
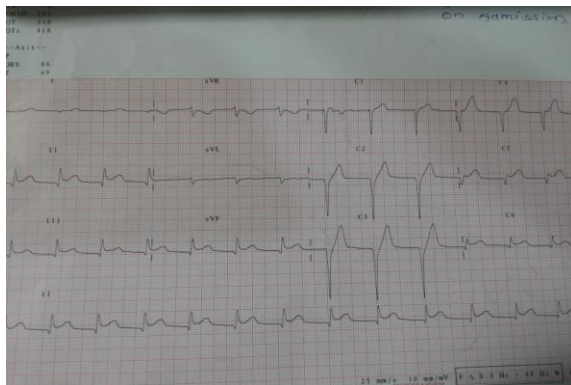
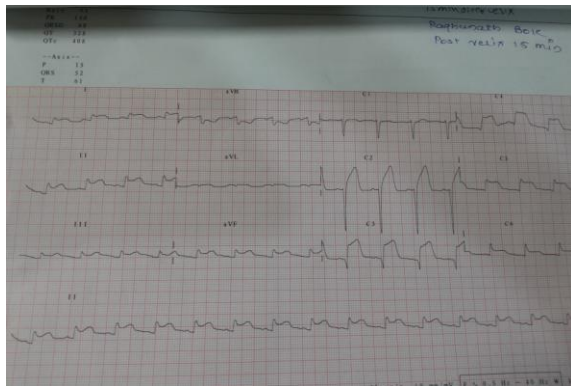
Mr R, 48 yr old male, without any previous cardiac illness or any other co morbidities, presented to the hospital with complaints of bee sting in the right wrist and right knee. He reached 3 hours after the bee sting. He complained of pain at the local site along

with heaviness of the retrosternal region, rash and profuse sweating.

On examination, he was alert and conscious. His pulse rate was 73/min regular, blood pressure: 80/50 mm Hg, temperature 98F and respiratory rate 20/min. cardiovascular examination was normal other than hypotension. Chest was clear and abdominal examinations were also within normal limits. He was neurologically stable.

On investigations, his routine complete blood counts and electrolytes were normal. Routine ECG showed ST segment elevation in leads II, III, aVF, V2, V3, V5 and V6 Cardiac enzymes were done, CPK MB was elevated by 1.5 times the upper limit of normal, but Troponin I was negative. A diagnosis of acute myocardial infarction involving the inferolateral wall was made and he was planned for medical thrombolysis. Inj Tenecteplase was given IV at a dose of 60mg bolus. Repeat ECG was done after 15 mins and 2 hours, which did

not show much change. However, the ECG done after 24 hours showed reduction in the degree of ST elevation in precordial leads and development of Q waves in II, III, aVF, V5 and V6. After 7 days of thrombolysis, patient was stable with blood pressure normalized, and ejection fraction was 30% with anteroinferior wall hypokinesia.



Discussion:

This case reports underlines the fact that in any patient of bee sting, we should evaluate any complaints that can be attributed to cardiac complications. This patient presented with retrosternal discomfort, which is a classical symptom of acute coronary syndrome.

Hymenoptera (bees, wasps and yellow jacket) are found worldwide and some of them are venomous animals. The main component of bee venom responsible for pain in vertebrates is the toxin *melittin*; histamine and other biogenic amines may

also contribute to pain and itching (1). Possible pathogenetic mechanisms include severe hypotension, rarely hypertension and coronary vasospasm with subsequent thrombosis of coronary vessels developed after the release of vasoactive, inflammatory and thrombogenic substances contained in the bee venom. This syndrome is also known as Kounis syndrome (2). There are many case reports that have shows myocardial infarction as a complication (3-5). In one of the reports, the patient had associated rhabdomyolysis (6). This association might point out to a common basic pathway involved. Larger data in the form of case series is required for further characterization.

References

1. Meier J, White J. (1995). *Clinical toxicology of animal venoms and poisons*. CRC Press, Inc
2. Puttegowda B, Chikkabasavaiah N, Basavappa R, Khateeb ST. Acute

myocardial infarction following honeybee sting. *BMJ Case Rep*. 2014 Apr 12;2014

3. Massing JL, Bentz MH, Schlessner P, Dumitru C, Louis JP. [Myocardial infarction following a bee sting. Apropos of a case and review of the literature]. *Ann Cardiol Angeiol (Paris)*. 1997 May-Jun;46(5-6):311-5

4. Taggar JS, Watson T, Musarrat K, Millane T. Kounis syndrome presenting as ST-segment elevation myocardial infarction following a hymenoptera (bee) sting. *Int J Cardiol*. 2009 Aug 14;136(2):e29-30

5. Ceyhan C, Ercan E, Tekten T, Kirilmaz B, Onder R. Myocardial infarction following a bee sting. *Int J Cardiol*. 2001 Sep-Oct;80(2-3):251-3

6. Mathew A, Chrispal A, David T. Acute myocardial injury and rhabdomyolysis caused by multiple bee stings. *J Assoc Physicians India*. 2011 Aug;59:518-20

Address for Correspondence

Dr. Rahul Surve

Department Of Medicine

BKL Walawalkar Hospital & Medical College,

Ratnagiri, Maharashtra