

CASE REPORT**Percutaneous Approach For Mandibular Angle Fracture Using Lag Screw.**

Pavan Kohli^a, Nisheet Agni^b, Asawari Modak^c, Sunil Nadkarni^d, Shrikant Sangle^e
a-Associate Professor, Department. of Orthopaedics, b,c- Department of dentistry ,
d- Consultant Orthopaedic Surgeon, e-Resident,
BKL Walawalkar Medical College and Hospital, Sawarde, Maharashtra, India.

Abstract:

Mandibular fracture are among the most common injuries to the facial skeleton with 6:2 proportion between mandibular and zygomatic fractures.¹ Facial injuries are clinically highly significant as the face provides anterior protection for the cranium, statistics shows that the maxillofacial injuries makes upto 48% of all forms of injuries of which road accidents and assaults are the most common causes.² The therapeutic goal of Mandibular fracture treatment is the restoration of anatomic form, function, with particular care to reestablishment of occlusion and facial esthetics, with least patient discomfort.

This article describes the new intervention and effectiveness of lag screw in the treatment of mandibular angle fracture using extraoral percutaneous approach.

Keywords:

Mandibular angle fracture, Percutaneous approach, Lag screw.

Introduction:

Fracture of the mandibular angle are plagued with the highest rate of complication of all bandages, splints, circummandibular wiring, extraoral pins. Semirigid fixation with transosseous wiring to rigid fixation and more lately back to semirigid fixation with miniplates³In recent years the treatment of mandibular fractures has led to the use of operative as well as conservative methods.

The traditional way of treating mandibular angle fracture involves either close reduction with MMF or open reduction and internal fixation with or without MMF. The current trend involves use of miniplates with monocortical screw in the treatment of mandibular angle fracture.

Although many studies have shown two miniplates to be more stable than a single miniplate, whether one or two miniplates should be used at the mandibular angle fracture is still debatable.^{4,5,6}

Extraorally, the approach, to open reduction and internal fixation was through a skin incision in the submandibular region. It has disadvantage of leaving scar and also puts facial nerve at the greater risk, though the advantage was better exposure and direct application of fixation plate.⁷

Another approach is, Transbuccal approach, the main advantage is that it result in no external scarring and also allows visualization and confirmation of desired occlusion during placement of bone plate.⁸

With all these different modalities of treatment of mandibular angle fracture, the aim of our study is to evaluate the effectiveness of a new technique of minimal approach using Lag screw for stabilization by compression that relies on bony buttressing of the fracture to

help stability. Other reason why mandibular body is suited to lag screw fixation is the thickness of the bony cortices which provides extremely secure fixation when screw are properly inserted, providing interframmmentary compression.

Review Of Literature

- 1) Paul G Tiwana et al done an analysis on 102 patients who underwent lag screw fixation of fracture of anterior mandible. Lag screw osteosynthesis of anterior mandibular fracture is a sensitive, facial, predictable and relatively in expensive method for internal fixation of indicated fractures.
- 2) Ellis E and Ghali GE (1991) reviewed 41 patients who had lag screw placed for anterior mandibular fractures and showed that it provides rigid internal fixation.
- 3) Ellis E and Ghali GE (1991) treated 30 patients who had lag screw placed for mandibular angle fracture, showed that it is an extremely useful, but technique-sensitive, method of providing rigid internal fixation.
- 4) Zachariades N, Mezitis M and Papademetriou I (1996) retrospectively evaluated 30 patients, treated with lag screw and concluded that 30% of patients developed complications which were minor, transient or both.
- 5) Ellis E (1996) showed that treating fractures of mandibular body using lag screw alone or with bony plates, concluded that it is a reliable technique when there is sufficient obliquity of fracture.
- 6) Kallela I, Ilzuka T, Laine, Lindquist C (1996) studied to evaluate clinical and radiological results after lag screw fixation of mandibular parasymphiseal and angular fractures, concluded that it is practical and effective way of fixing such

fractures internally.

Case Report

A case of RTA reported to ER of the B.K.L.Walawalkar.Hospital. Radiological and clinically the patient was diagnosed with displaced, unilateral, right side mandible angle fracture and also undisplaced intraarticular left side fracture of clavicle. While the fracture of the clavicle was managed conservatively with strapping and immobilization, the fracture of angle of mandible was managed by novel technique using a cannulated, cancellous lag screw. Complete case history was taken. General examination was done to rule out any other injury present. Local examination was done to look for jaw opening, tenderness at fracture site, teeth in line of fracture and presence of infection. Required investigation as complete blood count, random blood sugar was done. X-rays as PA mandible, lateral oblique both right and left side of mandible, CT mandible.

Surgical technique:

Patient was taken to the operation theatre, where he was scrubbed and draped as per routine. After intubation, antibiotic ointment was put in both eyes and sterile gauze pack was placed.

The site of insertion was marked with Bonny's ink about 1.5-2cms below and parallel to the inferior border of mandible. Surgical site was infiltrated with local anaesthetic solution containing 2% lignocaine with 1:80,000 adrenaline. Application of this technique relies on tension band principle which can be achieved by the placement of interdental wire and resistance of intercusp relationship of teeth after intermaxillary fixation.

In this case, interdental wiring was done using eyelet for intermaxillary fixation to restore primary occlusion. A 1cm long incision was made at previously anticipated location, so as

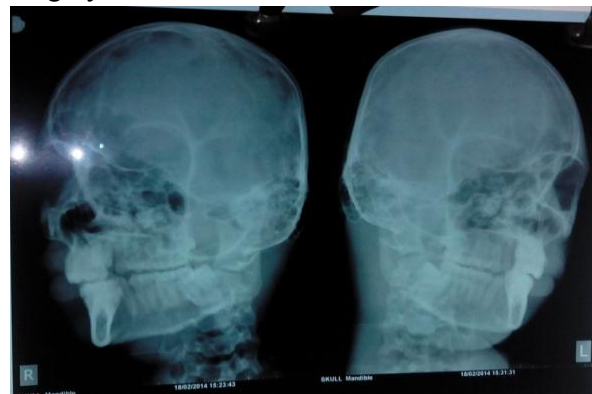to drill the cortex. Proximal segment of bone was drilled with drill bit and a guiding wire was passed through the hole to access proper insertion path of lag screw. Drilling the cortex is the most important step in this technique. The factors to be considered are that -1)Drill bit should always be intraosseous.2)Point of drill should be equidistant from fracture line so that the threaded part of the screw engages the other fragment and produce static interfragmentary compression and satisfactory fixation of fracture.¹ 3)Angulation and depth must be in such a way that-a)should not disturb the underlying mandibular nerve and facial artery. b) Should not interfere with the bony structures such as mandibular canal, tooth roots. c) Should not breach lingual cortex beyond its limits. d) Should be always at right angle to the line of fracture.

For angle fracture an extraoral approach that is submandibular, gliding hole was made just 2mm below the apices of the posterior teeth in relation with first molar and drill was performed, selection of proper point of entry for drill bit in the buccal cortex was placed sufficiently away from fracture line so that ample amount of bone is present between the head of screw and the fracture line after drill and counter-sink. A proper care was taken not to disturb the underlying structures as mentioned above. Through the hole a guiding 'k' wire was inserted to guide the path of insertion of lag screw. The path of insertion is predicted by securing the terminal screw threads in bone that is dense enough to provide rigid fixation. The proper angulations and path of insertion of lag screw is determined by using 'k' wire and taking X-rays during procedure. Drilling through the second fragment was the next step, with the drill bit seated in near fragment to obtain same angulations as in first. A 'k' wire was inserted

through drilled hole and screw length was determined. The hole in the far segment was tapped using long tap. After selecting the appropriate length of screw, it was inserted on a screw driver into the screw hole. The outer hole was free of threads so that screw slips through until it contacts the threads in far segment. Thus when tightened the screw would compress the two segments of bone together.

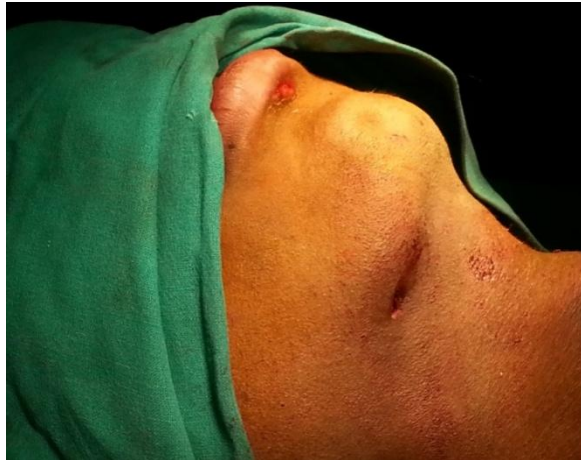Once the adequate fixation was achieved the skin was closed with a single suture. The MMF was released and patient was maintained on soft diet.

The following X-ray was taken prior to the surgery to determine the site of fracture.



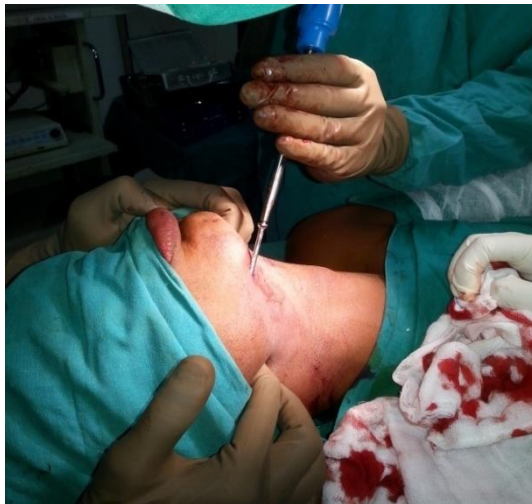Following are the photographs that were taken during operative procedure.

Fig (1) shows the extra oral percutaneous

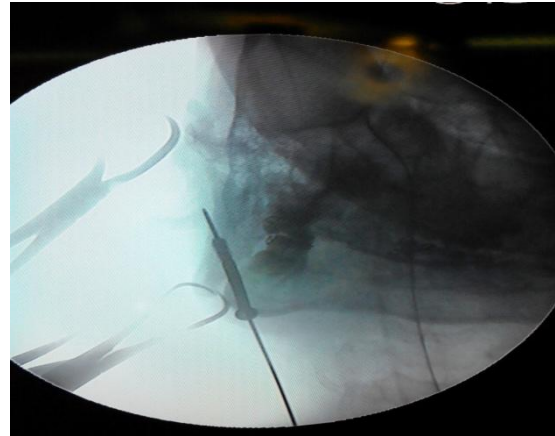


approach used for the insertion of lag screw.

Fig(2) shows the insertion of guiding wire that would determine the path of insertion of lag screw.

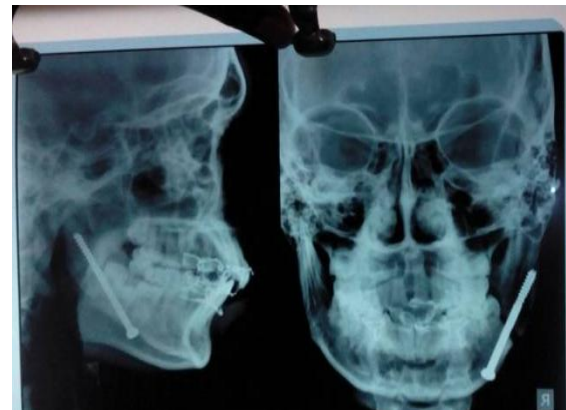

Radiographic view of path of insertion of lag screw using 'k' wire as guiding wire. Fig (3)



X-Rays showing the proper placement of lag screw after surgery Fig. (4)

Discussion:



Management of mandibular angle fracture is often challenging and results in the highest complication rate among fracture of the mandible. Optimal treatment for angle fracture remains controversial.⁶ historically, treatment of mandible fracture includes intraoperative maxillomandibular fixation (MMF) along with rigid internal fixation. More recently, non compression manipulates which produces only relative stability, have gained popularity. The absolute necessity of intraoperative MMF as an adjunct to internal fixation has also become

controversial.^{9,11} The use of single non compression miniplate for treatment for mandibular angle fracture had a high complication rate.^{9, 11}

When mandibular angle fracture, treated with two miniplates complication rates was 2.1% as compared to treated with one miniplate with 26.3% complication rate.¹²

When two mini dynamic compression plates were placed through transoral incision without MMF, complication rate found was 29% and results are unpredictable.¹⁴ Any tooth in fracture line was removed if it was infected, fractured or was interfering with reduction.^{16,17}

The complication rates were within acceptable limits even when treated after 24 hours of injury, proving no correlation between time, or injury and treatment given.¹⁸

The present study describes a new intervention and management of mandible angle fracture using lag screw. The approach used was percutaneous with minimum or just a small hole type incision for insertion of screw. The various advantages that were achieved by using this technique are :- 1) the most important was the cosmetic approach of no scar formation caused because of incision.2) innovative drilling and tapping lag screw ensures superior compression across the fracture site providing proper stability.3) Low profile head of the lag screw prevents soft tissues irritation and also preserves blood supply.4) Comprehensive system requires minimal instrumentation while reducing the operative time for surgeon.5) Less post-operative complication hence the hospital stay of patient is reduced. Last but not the least the technique is financially affordable.

References:

1. Sanjay Jadwani and Snehal Bansod.Lag screw fixation of fracture of the anterior mandible.A new minimal access technique. J.Oral.Maxillofac.Surg Jun2011;10(2):176-180
2. Bochylogyros NP. A retrospective study of 1521 mandibular fracture. J.Oral Maxillofac Surg 1985;43:597-599
3. Fonseca Raymond J and Robert V Walter.Oral and Maxillofac Trauma, Pennsylvania, W.B.Saunders Company,1997;2nd edition vol-1:474-478
4. Kroon HM et al. The use of miniplates in mandibular fracture. An in vitro study.J.Cranio Maxillofac Surg 1991;91:199-204
5. Choi BH, Kim KN, Yoo JH and Kang HS. Stability test of two miniplates fixation technique for mandibular angle fractures. As in vitro study. Journal of cranio Maxillofac Surg 1995;23:122-125
6. Gear AJ, Apasova E, Schmitz JP, Suhubert W. J. Oral Maxillofac Surg 2005 may 63(5):0555-63
7. Vincent S.Toma et al. Transoral versus extraoral reduction of mandible fractures : A comparison of complication ratesand other factors. Otolaryngology.Head and Neck surgey 2003;18:215-219
8. Eric J.Dierks: Transoral approach to fracture of the mandible. Laryngoscope 1987;97:4-6
9. Ellis Edward III. Treatment methods for fractures of the mandibular angle. Int.J.Oral Maxillofac Surg 1999;28:243-252
10. Niederdellmann.H, Akuamoaboateng E, Uhling G. Lag screw osteosynthesis: Anew procedure for treating fracture of mandibular angle. J.Oral Maxillofac Surg 1981;9:938-940
11. ElliS E, Walker LR: Treatment of mandibular angle fracture using one non compression miniplate .J.Oral Maxillofac

- Surg 54:864,1996
12. Levy FE et al. Monocortical miniplate fixation of mandibular angle fracture. Arch Orolaryngol Head Neck Surg 1991;117:149-154
 13. Ellis Edward III and GE Ghali et al. Lag screw fixation of mandibular angle fracture. J.Oral Maxillofac Surg 1991;49:234-243
 14. Ellis Edward III and M Karas et al. Treatment of mandibular angle fracture using two mini dynamic compression plates. J Oral Maxillofac Surg 1992;50:958-963
 15. Ellis Edward III et al. Treatment of mandibular angle fracture using AO reconstruction plate. J Oral Maxillofac Surg 1993;51:250-254
 16. Nakamura S, Yashuharu T, Masuichiro O. Complication of miniplates osteosynthesis for mandibular fracture. J Oral Maxillofac Surg 1994;32:233-239
 17. Stefan Berg, Hans Dieter Pape. Teeth in fracture line. Int J Oral Maxillaofac Surg 1992;21:145-146
 18. Pradeep Pattar, Sujith Shetty, Saikrishna Degala. A prospective study on management of mandibular angle fracture. J Oral Maxillofac Surg 2013

Address for Correspondance:

*Dr. Pavan Kohli,
Associate Professor,
Department of Orthopaedics,
BKL Walawalkar Rural Medical College
and Hospital, Sawarde, Maharashtra, India.*